



PATIENT

Morissa Valley Animal
Rescue

SPECIES

Canine

BREED

Bichon Frise

SEX

Female

AGE

10 years

WEIGHT

10.8lbs

INTERPRETED BY

Maggie Machen Lamy,
DVM, DACVIM
(Cardiology)

IMAGING PERFORMED BY

Mark van Campen,
DVM

HOSPITAL NAME

Mississippi Mills
Animal Hospital

REFERRING VET

Dr. van Campen

INVOICE

45633

DATE

11/4/25

PRESENTING CLINICAL SIGNS

History: In rescue recently. Grade V/VI heart murmur. Asymptomatic. CXR: no congestion. VHS 10.9 VLAS 2.2 (flattened ventral chest so hard to interpret overall cardiac size). Assess prior to anesthesia.

ECHOCARDIOGRAM FINDINGS

2D, m-mode, color flow and doppler imaging is available. Diffuse thickening of mitral valve leaflets (anterior>posterior) with mild prolapse into the left atrial lumen. Moderate eccentric mitral regurgitation with moderate left atrial dilation. Normal MR velocity. Mildly increased LV diameter with adequate myocardial function. The tricuspid valve appears mildly thickened, with trace tricuspid regurgitation. Normal velocity. Normal right atrial and ventricular diameter. The pulmonic and aortic valves are normal in morphology and mobility. Normal pulmonic and aortic outflow velocities. No aortic or pulmonic insufficiency. No pericardial or pleural effusion noted. No cardiac tumors observed.

CARDIAC CHART

CANINE CARDIAC PARAMETERS	MR VMAX (m/s)	TR VMAX (m/s)	LA/AO (Boon method)	LA/AO (Heart Base; Swe)	FS (%)	EF (%)	EPSS (cm)
NORMAL PARAMETER	4.5-5.5	<2.7	1.3	<1.6	28-40	40-100	<0.6
PATIENT	5.5	2.2	NM	1.8	47	90	NM
CANINE CARDIAC PARAMETERS	HR (BPM)	AV VMAX (m/s)	PV MAX (m/s)	BODY WEIGHT (kg)	LA 2D short axis Base view (cm)	LVIDd Avg; 2D and m-mode short axis (cm)	LVIDs Avg; 2D and m-mode short axis (cm)
NORMAL PARAMETER	50-100	0.7-1.7	0.7-1.6	BELOW	BELOW	BELOW	BELOW
PATIENT	NM	1.4	1.0	4.9	2.5	3.8	2.0
*Normal chamber parameters expressed as a mean value (SD)				3	1.27 (5.3)	2.46 (2.46)	1.36 (5.5)
BODY WEIGHT DEPENDENT PARAMETERS				5	1.40 (4.5)	2.74 (5.2)	1.60 (4.7)
<i>*Note: All measurements based upon multi-modal images and methods. An average value is reported.</i>				10	1.50 (3.8)	3.27 (3.5)	2.06 (3.1)
				15	1.83 (2.0)	3.71 (2.4)	2.43 (2.1)
				20	2.02 (1.9)	4.14 (2.2)	2.80 (2.0)
Adapted from June Boon, Veterinary Echocardiography, 1998				25	2.18 (2.4)	4.48 (2.9)	3.10 (2.5)
Rishniw M and Hollis NE, J Vet Intern Med 2000; 14:429-435				30	2.33 (3.3)	4.83 (3.9)	3.39 (3.4)
Hansson et al, Vet Rad and Ultrasound 2002				35	2.48 (4.3)	5.17 (5.0)	3.69 (4.5)
Bonagura et al. Echocardiography: principles of interpretation, Vet Clin North Am 15:1177, 1995				40	2.62 (5.2)	5.48 (6.1)	3.96 (5.4)
				50	2.88 (7.1)	6.07 (8.3)	4.46 (7.4)

INTERPRETATION OF THE FINDINGS & FURTHER RECOMMENDATIONS

Chronic degenerative valve disease causing moderate mitral and trace tricuspid regurgitation. Moderate left atrial enlargement indicates there is relatively low risk for imminent complication; however, risk for progression to spontaneous congestive heart failure in the future is elevated. No additional issues such as pulmonary hypertension are identified.

Given the risk for progression and results of the EPIC trial, Pimobendan is indicated in this patient as below. Assessment of progression in the future will help predict long term outcome; however, prognosis is guarded at this stage (B2). Fifty percent of stage B2 patients typically develop CHF within 2-2.5 years of diagnosis. The median time to development of CHF in B2 cases treated with pimobendan is 3.5 years.



PATIENT

Morissa Valley Animal
Rescue

SPECIES

Canine

BREED

Bichon Frise

SEX

Female

AGE

10 years

WEIGHT

10.8lbs

INTERPRETED BY

Maggie Machen Lamy,
DVM, DACVIM
(Cardiology)

IMAGING PERFORMED BY

Mark van Campen,
DVM

HOSPITAL NAME

Mississippi Mills
Animal Hospital

REFERRING VET

Dr. van Campen

INVOICE

45633

DATE

11/4/25

Omega fatty acid supplementation and mild salt restriction may also be of some long-term benefit. Monitor for development of a progressive cough, labored breathing, exercise intolerance or collapse episodes.

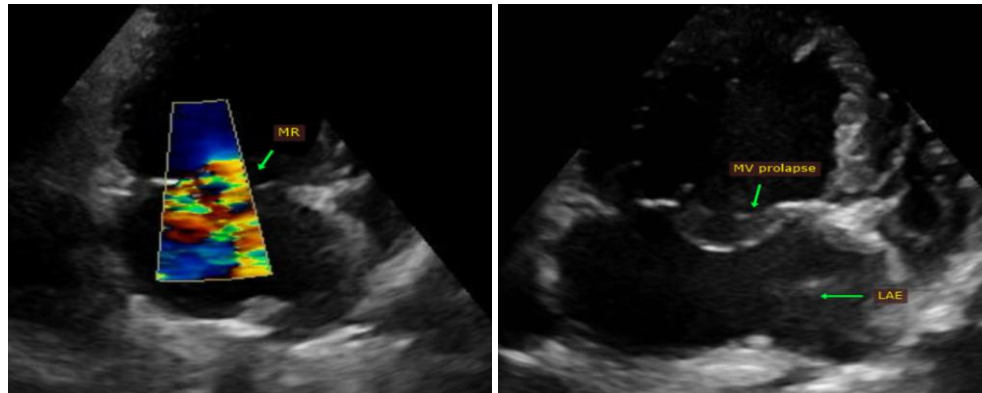
Once on the medication for 3-5 days, anesthetic risk is considered mildly elevated. Cardiac protective drug choices (opioid/benzodiazepine premedication, Propofol or alfaxalone induction, iso or sevo gas) are recommended. Monitor for arrhythmias, hypotension, and hypoxia both intra and post-operatively and intervene as necessary. Judicious IV fluid rates are recommended to avoid fluid overload. Avoid heart rate stimulating drugs such as atropine unless clinically indicated.

PLAN

Baseline BP recommended. Institute heart muscle support Pimobendan 0.25-0.3mg/kg PO q12h.

Recommend monitor for progression with a recheck echocardiogram in 6 months, sooner if any development of clinical signs.

IMAGES



The information and recommendations provided are based on the images presented by the referring veterinarian. No evaluation can be communicated regarding pathology that was not visible in the image/video clips provided.

Thank you for this referral. This report was generated using transcription software, and minor dictation errors may be present. If the clinical or image interpretation does not parallel your findings or if I can be of any further assistance, please contact me.

Maggie Machen Lamy, DVM
Diplomate of the American College of Veterinary Internal Medicine (Cardiology)
info@sonopath.com